Annals of Health Research

(The Journal of the Medical and Dental Consultants' Association of Nigeria, OOUTH, Sagamu, Nigeria)

CC BY-NC
Volume **12, Issue 3: 406-417**
September 2026
doi: 10.30442/ahr.1203-11-343

CASE REPORT

Endoscopic resection of Sinonasal Squamous Cell Papilloma: Report of a rare case

Shuaib K Aremu[1,2], Theophilus O Esan[2], Oladipo Omoseebi[3], Abdulwasiu Salman[4], Kehinde O Ojo [5]

[1]Department of ENT, College of Medicine and Health Sciences, Afe-Babalola University, Ado- Ekiti, Nigeria

[2]Department of ENT, Federal Teaching Hospital Ido-Ekiti, Nigeria

[3]Department of Anatomic Pathology, College of Medicine and Health Sciences, Afe Babalola University, Ado Ekiti, Nigeria

[4]Department of ENT, University of Ilorin Teaching Hospital, Ilorin, Nigeria

[5]Department of Dentistry, College of Medicine and Health Sciences, Afe-Babalola University, Ado- Ekiti, Nigeria

Correspondence: Dr Shuaib Kayode Aremu, Department of ENT, Afe Babalola University, Ado-Ekiti, Nigeria. Email: aremusk@abuad.edu.ng, ORCID number: 0000-0002-0165-6867

Citation: Aremu SK, Esan TO, Omoseebi O, Salman A, Ojo KO. Endoscopic resection of Sinonasal Squamous Cell Papilloma: Report of a rare case. Ann Health Res 2026;12(3):407-418. https://doi.org/10.30442/ahr. 1203-11-343

Summary

Sinonasal papilloma is a rare benign epithelial tumour of the nasal cavity and paranasal sinuses with a tendency for local invasion and recurrence. Complete surgical excision is essential to prevent recurrence and malignant transformation. We present a thirty-eight-year-old Nigerian woman with a two-year history of left-sided nasal obstruction that progressed to bilateral obstruction, with nasal growth, hyponasal speech, anosmia and occasional epistaxis. Examination revealed a pale, non-tender mass occupying the left nasal cavity with septal deviation to the right. Endoscopic-assisted examination under anaesthesia confirmed a mass occluding the left nasal cavity. She underwent endoscopic intranasal tumour clearance and was discharged on the second postoperative day. She recovered satisfactorily without complications. Endoscopic resection may be an effective, less invasive option for managing sinonasal papilloma, particularly in resource-limited settings where equipment and expertise are available.

Keywords: Sinonasal papilloma, Nasal obstruction, Endoscopic surgery, Nasal tumour, Epistaxis

Introduction

Sinonasal papilloma refers to a group of benign epithelial lesions that arise from the lining of the sinonasal tract. They are also termed Schneiderian papillomas (SP), after the Schneiderian membrane (the sinonasal mucosa), which takes its name from the German anatomist Conrad Victor Schneider (1614–1680), whose work in the seventeenth century established that nasal mucus is produced by the nasal mucosa rather than draining from the brain.[1] Ward provided the first description of SP of the nose in 1854.[2] There are three types of sinonasal papilloma, which include inverted, exophytic, and oncocytic papilloma. These three subtypes of SP are distinguished by their clinical and histopathological features.[3] Ringertz first reported that Schneiderian papillomas tend to grow inward into the underlying connective tissue stroma, a feature that sets them apart from other papillomas.[4] The case report aims to highlight the clinical presentation, diagnostic evaluation, and successful endoscopic management of sinonasal squamous cell papilloma, illustrating the feasibility of a minimally invasive approach in this patient.

Case Report

This is a case of a 38-year-old woman who presented to our outpatient department on account of a bilateral nasal blockage of 2 years' duration, which was insidious in onset, initially involving the left nasal cavity associated with growth. The blockage progressively worsened to involve the right side. There was an associated history of scanty, yellowish, non-foul-smelling nasal discharge with a history of a single episode of spontaneous epistaxis. There was associated mouth breathing, snoring, postnasal dripping, anosmia, and hyponasal speech. There was no history of excessive sneezing or nasal itching. She had no associated otologic or throat symptoms. There was no previous history of nasal surgeries. There was no history of exposure to ionizing radiation. No history of weight loss or anorexia. There was no family history of cancer or cancer-related death. She is a known hypertensive patient on antihypertensive medications. She neither smokes nor consumes alcoholic beverages. Physical examination revealed a young woman who breathes through her mouth. Nasal examination revealed loss of the normal pyramidal shape of the nose with loss of nasal patency.

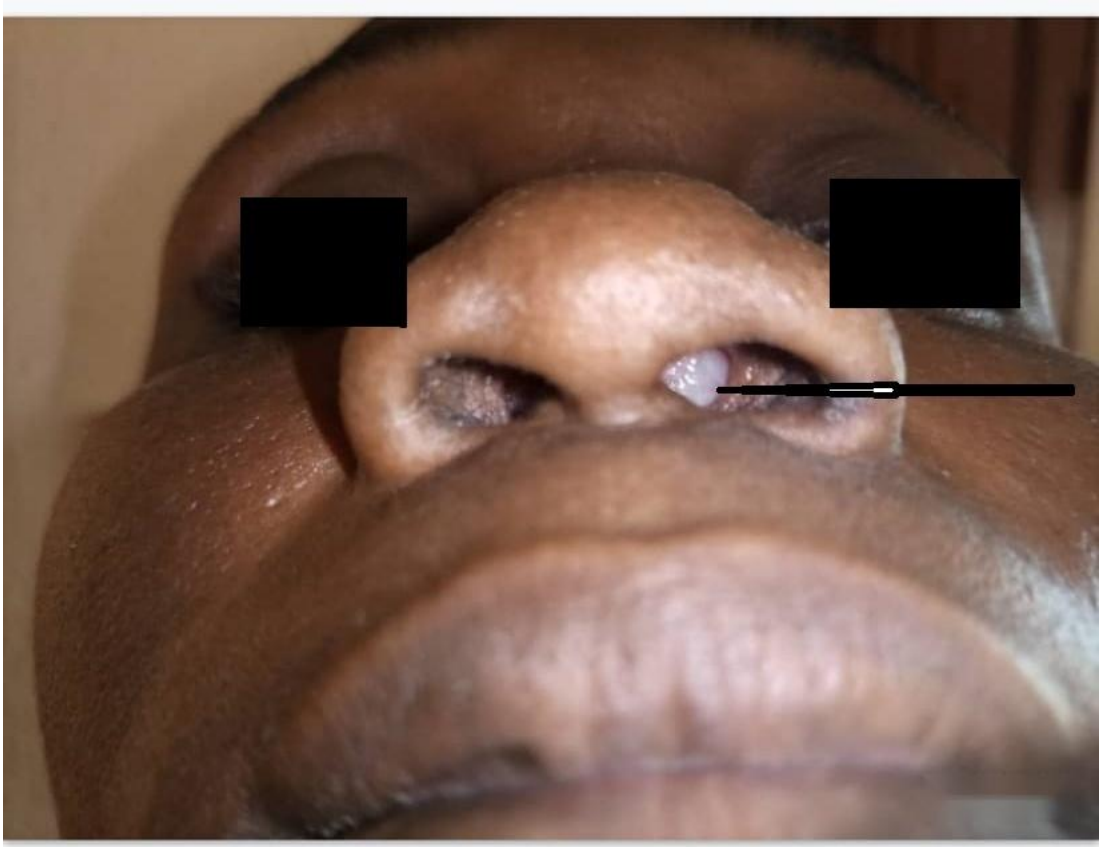

Figure 1. Pale, shining mass in the left nasal cavity, not sensitive to touch and no contact bleeding, pushing the nasal septum to the right side

A pale, shiny mass was present in the left nasal cavity, non-tender and non-bleeding on contact, displacing the nasal septum to the right (Figure 1). Oral cavity and oropharyngeal examination revealed tenting of the soft palate more on the left than the right side. Otological examinations were essentially normal. The tympanic membranes were intact and shiny**.** Head and neck examinations were essentially normal. The patient had a computed tomography (CT) scan of the paranasal sinuses done, which revealed an 85 × 52 × 50 mm well-defined peripherally enhancing mass in the left nasal cavity causing expansion of the nasal cavity and extending into the left maxillary sinus, nasopharynx and choana, left sphenoid sinus and the sella (Figure 2).

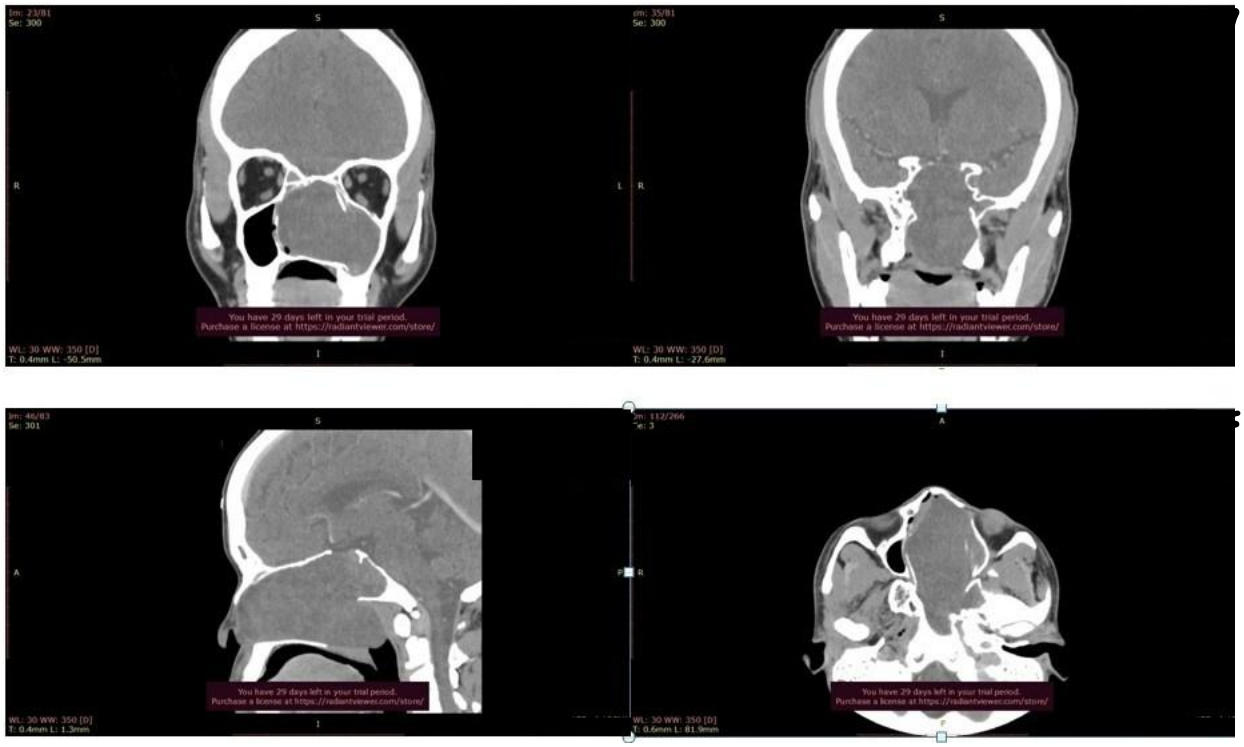

Figure 2. Computed Tomography Scan of the Paranasal sinuses showing an 85 × 52 × 50 mm well-defined, peripherally enhancing mass in the left nasal cavity extending into the left maxillary sinus, nasopharynx, choana, left sphenoid sinus, and the sella

There is pressure erosion of the left maxillary sinus wall, sella, and the anterior walls of the sphenoid sinus. There was bowing of the nasal septum to the right side. There was radiological evidence of bilateral frontal and right ethmoid sinusitis. The right maxillary sinus appeared clear. The optic canals and the position of the cavernous carotids with respect to the sphenoid sinus were within normal limits. The orbits and their contents were normal. A diagnosis of sinonasal papilloma (likely inverted type) based on clinical and radiologic findings was made.

A paranasal biopsy of the mass was performed in the clinic under local anaesthesia using topical lignocaine, and its histopathology showed polypoid tissue lined by stratified squamous epithelial cells with no atypia. The stroma was fibrovascular and oedematous, containing small-sized blood vessels. Differential diagnoses including inflammatory nasal polyps, antrochoanal polyp, and sinonasal malignancy were considered

unlikely based on the clinical presentation, endoscopic findings and radiologic features, and on the absence of atypia on histopathology. Definitive diagnosis was established by histopathological confirmation of sinonasal papilloma**.**

She was worked up for surgery, and ancillary investigations, including full blood count, electrolytes, urea and creatinine, and clotting profile, were all within normal limits. Serological screening revealed positive hepatitis B surface antigen (HBsAg), while Retroviral and hepatitis C virus screenings were negative.



Figure 3a **Figure 3b**

Figure 3a. Bulbous right nasal septum and engorged inferior turbinate causing complete nasal blockage

Figure 3b. Polypoidal mass occupying the whole of left nasal cavity

The patient subsequently underwent endoscopic-assisted tumour resection under general anaesthesia. Intraoperative findings were that of a pale, shining mass occupying the whole of the left nasal cavity, erosion of the lateral wall and a bridge in the roof, revealing an intact dura, and deviation of the septum to the right side (Figure 3a and 3b). The mass was carefully excised using Blakesley forceps under endoscopic guidance (Figure 4).



Figure 4. Endoscopic-assisted left Intranasal clearance

An anterior nasal pack was inserted to secure and maintain haemostasis after clearance. She responded well postoperatively; anterior nasal packing was removed on day 1 after surgery. There was no episode of epistaxis following the removal of the pack. Postoperative packed cell volume was 32%. She improved postoperatively and was discharged on the second postoperative day. Figure 5 shows the polypoidal mass removed from the left nasal cavity and left maxillary sinus, which was sent for histology. The report showed polypoidal tissue lined by stratified squamous epithelium with no atypia. The stroma was fibrovascular and oedematous and contained small-sized blood vessels (Figure 6). The patient was placed on regular follow-up with periodic endoscopic nasal examinations as surveillance for recurrence. Follow-up visits were scheduled at short intervals initially (4–6 weeks, then every 3–6 months). Patient education on symptom recognition was also emphasized. In the event of recurrence, early revision endoscopic excision was planned. Long-term surveillance was considered essential given the known potential for recurrence of sinonasal papilloma.



Figure 5. Polypoidal mass cleared from left nasal and maxillary cavities

Discussion

Sinonasal papilloma is a benign epithelial neoplasm of the nasal cavity and paranasal sinuses. It behaves in a locally aggressive manner, tends to recur after excision, and carries a small but real risk of malignant change.[3–5] Our patient presented with a long-standing, progressive nasal obstruction that began on one side, accompanied by hyponasal speech, loss of smell, and occasional nosebleeds, a pattern in keeping with previously reported presentations.[3] A unilateral, pale, polypoidal intranasal mass that displaced the septum raised suspicion of a neoplasm rather than ordinary inflammatory nasal polyposis.

Imaging in this patient showed a well-defined, expansile mass that extended into neighbouring structures and caused pressure erosion of bone. This pattern is typical of sinonasal papilloma and helps to distinguish it from malignant tumours, which more often cause destructive bone invasion.[6] Histopathology confirmed the diagnosis and remains the definitive diagnostic standard.[7]

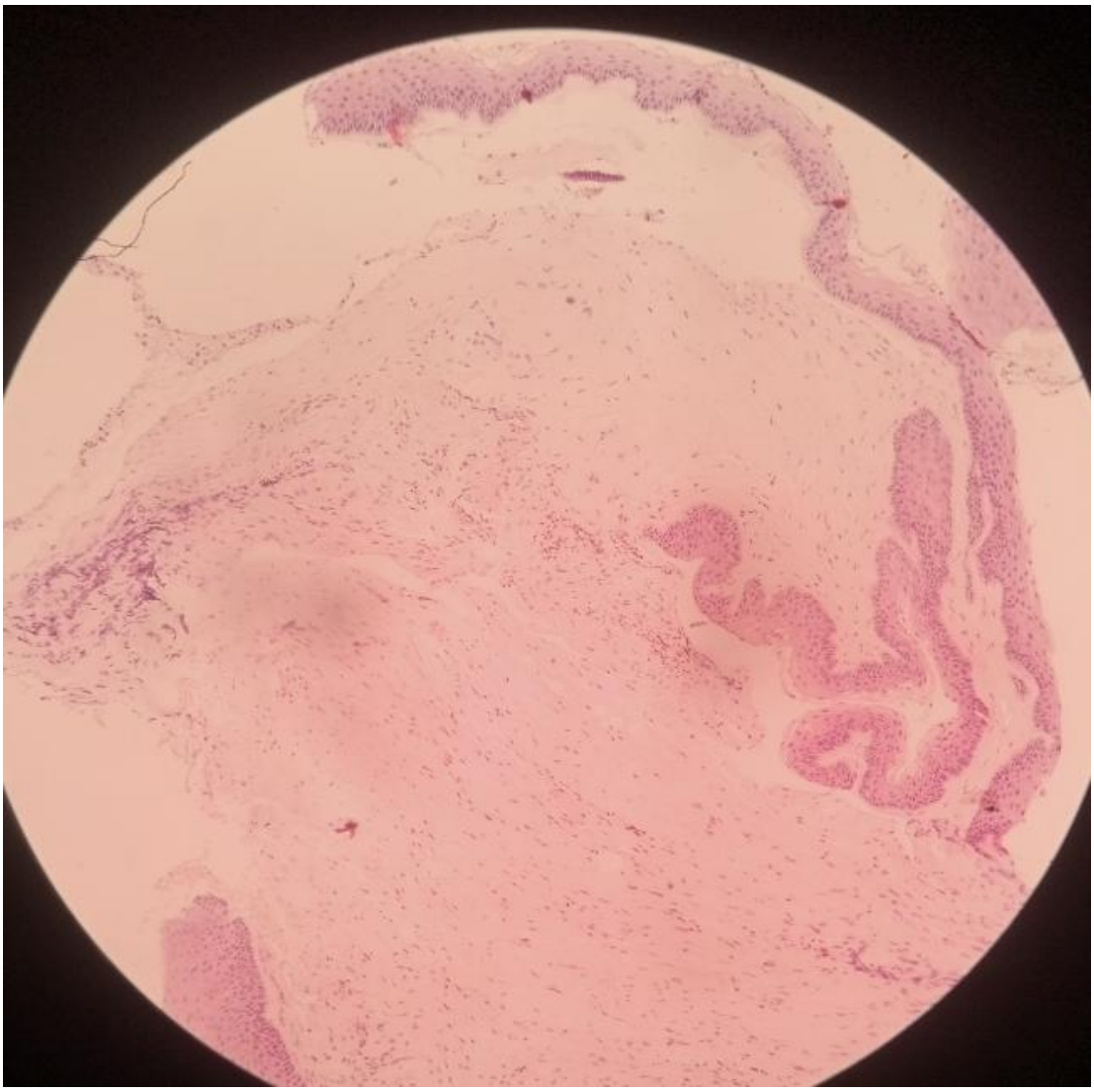

Figure 6. Polypoidal tissue lined by stratified squamous epithelial cells with no atypia.

The Stroma is fibrovascular and edematous, containing small-sized blood vessels

Inverted papilloma is the most common of the three subtypes, and its endophytic growth pattern and relatively high recurrence potential make complete excision and careful follow-up essential.[3,4] In this patient, the endoscopic-assisted approach gave a clear view of the extent of the tumour and its site of attachment, allowing precise and complete removal while sparing normal anatomy. Endoscopic surgery is generally associated with lower morbidity, a

shorter hospital stay, and faster recovery,[8] consistent with the uncomplicated course and discharge on the second postoperative day seen here.

Because these tumours can recur, especially when disease is extensive, long-term surveillance is essential.[3–5] Our patient was therefore enrolled in regular follow-up with periodic endoscopic examination. This case indicates that endoscopic management can give favourable results even in resource-limited settings, provided the necessary expertise is available.

Sinonasal Inverted Papilloma (IP): Among the three recognised subtypes of sinonasal papilloma, inverted papilloma (IP) is the most frequently encountered. [4,6,9] Macroscopically, it usually appears as a bulky, greyish lesion with a lobulated surface. Histologically, the tumour is characterised by inward proliferation of thickened epithelial cells into the underlying stroma, with preservation of the basement membrane.[7,10] The lining epithelium commonly shows respiratory-type differentiation, although areas of squamous metaplasia may also be present.[7,10] Transitional metaplasia has been proposed as an intermediate stage in the development of these lesions, linking the normal pseudostratified ciliated columnar epithelium with stratified squamous epithelium.[10] The pattern of epithelial growth, together with the degree of inflammatory cell infiltration, is regarded as relevant to the biological behaviour of the tumour.[7,10,11]

Whether human papillomavirus (HPV) infection contributes to the development of IP has attracted considerable research interest.[1,12,13] Studies have sought to clarify how HPV relates to IP and to its malignant transformation. Bayne and Olekszyk described an HPV-16-positive bilateral exophytic papilloma, which supports a possible aetiological role for HPV in sinonasal papillomas.[13] HPV types are conventionally grouped by oncogenic potential: types 16 and 18 are high-risk, whereas types 6 and 11 are low-risk.[7] HPV DNA has been detected in IP, and also in IP coexisting with squamous cell carcinoma (SCC), implying that the virus may be involved in both the pathogenesis of papilloma and its malignant progression.[4,14] In a retrospective study, integration of the viral genome was demonstrated in some IP specimens with SCC, further suggesting an active role for HPV in malignant transformation.[13] Taken together, these findings suggest that HPV may contribute to malignant change, to the development of the lesion and to its recurrence.

Exophytic Papilloma: Exophytic papilloma (EP) is an uncommon subtype that typically arises from the anterior nasal septum, where it forms a greyish-tan polypoid mass on a narrow stalk.[14] Histologically, it shows papillary fronds with fibrovascular cores lined by stratified squamous epithelium.[13] In contrast to IP, the surface epithelium may show keratinisation.[3,15] Because EP is rare, adequately sized studies are difficult to carry out, and most of what is known comes from individual case reports. Bayne and Olekszyk described a 48-year-old man with alcohol use and a smoking history exceeding 30 pack-years, who presented with perennial rhinitis, intermittent right-sided epistaxis and right nasal obstruction and was found to have a right anterior nasal mass.[13] Excisional biopsy revealed two further lesions, on the anterior septum and on the wall of the right maxillary sinus; histology confirmed exophytic papilloma, HPV-16 was detected, and he was followed with serial nasal endoscopy.[13]

According to the WHO classification, EP is more common in males than in females.[2,7] Several features set it apart from inverted and oncocytic papillomas: it arises on the nasal septum, usually presents between the third and fifth decades of life, and is associated with low-risk HPV types.[2,7] Its risk of malignant change is very low, although rare transformation has been reported.[16] The case of Bayne and Olekszyk is particularly unusual because the disease was bilateral.[13] Treatment typically consists of complete endoscopic endonasal excision, including the mucosal site of attachment on the septum, to minimise recurrence; medial maxillectomy is reserved for tumours involving the lateral nasal wall or maxillary sinus.[4,8,17]

Oncocytic Papilloma (OP): Oncocytic papilloma is the rarest of the three sinonasal papilloma subtypes. [17–19] It has also been reported at extrasinonasal sites such as the middle ear. [20,21] It is prone to recurrence, and most often arises in the maxillary sinus.[19] In a retrospective series, Lilja et al. examined its clinical features, focusing on recurrence patterns and risk factors.[19] The maxillary sinus was the site of origin in 60% of cases. Overall, 39% of tumours recurred, at a median of 25 months after surgery. Recurrence was more frequent in smokers than in non-smokers (75% vs 31%), in patients with purulent rhinosinusitis at primary surgery than in those without (60% vs 31%), and in sinus-based than in nasal cavity tumours (45% vs 29%).[19] However, none of these differences reached statistical significance, and no malignant transformation was seen during follow-up.

Endoscopic medial maxillectomy is generally reserved for lesions that involve the maxillary sinus or lateral nasal wall and have a defined attachment.[4,8,17] Although imaging in our patient showed extension into the left maxillary sinus, nasopharynx and sphenoid sinus, the mass was polypoidal and was removed completely by intranasal endoscopic clearance alone, so a medial maxillectomy was unnecessary.

Conclusion

This case highlights the typical clinical presentation, diagnostic approach, and successful management of sinonasal papilloma in an adult patient. The use of endoscopic surgical resection allowed complete tumour clearance with minimal morbidity, rapid recovery, and good short-term outcome. Careful clinical evaluation, supported by imaging and confirmed by histopathology, remains essential for accurate diagnosis and appropriate management. Given the known risk of recurrence, regular postoperative endoscopic follow-up is crucial. This report supports the feasibility of endoscopic management of sinonasal papilloma, particularly in settings where expertise is available.

Recommendation: There is a need for further research on the etiologic factors, therapeutic goals and clinical guidance. Long-term follow-up is essential for early detection of recurrence.

Ethics statement: Ethical approval for this case report was obtained from the Research and Ethics Committee of Afe Babalola University Multi-System Hospital, Ado-Ekiti, Nigeria (Ref. No: AMSH/REC/26/62/141). Written informed consent for publication of the case details and accompanying images was obtained from the patient. The report was prepared in accordance with the Nigerian National Code of Health Research Ethics and with reference to the CARE guidelines**.**

Authors' Contributions: SKA, TOE and OO conceived the research and designed the study. SKA, SA and KOO drafted the manuscript. All the authors revised the manuscript for sound intellectual content and approved the final draft of the manuscript.

Funding: The manuscript is self-sponsored by the authors

Acknowledgement: The authors appreciate the contributions of the clinical and theatre staff of Federal Teaching Hospital, Ido-Ekiti, for their support in the evaluation, surgical management, and postoperative care of the patient. We also acknowledge the academic staff of Afe Babalola University Ado-Ekiti for their guidance in manuscript preparation and assistance with the literature review.

Conflicts of interest: None

Publication history: Submitted 18 May 2026. Accepted 27 August 2026

References

1. Franchi A, editor. Pearls and pitfalls in head and neck pathology. Cambridge: Cambridge University Press; 2019. doi:10.1017/9781316402078
2. Thompson LDR, Müller S, Nelson BL. Diagnostic pathology: head and neck. 2nd ed. Philadelphia: Elsevier; 2022.
3. Archang M, Chew L, Han AY, Sajed D, Vorasubin N, Wang M. Sinonasal papillomas: 10-year retrospective analysis of etiology, epidemiology, and recurrence. Am J Rhinol Allergy. 2022;36(6):827–834. doi:10.1177/19458924221116441
4. Eide JG, Welch KC, Adappa ND, Palmer JN, Tong CCL. Sinonasal inverted papilloma and squamous cell carcinoma: contemporary management and

patient outcomes. Cancers (Basel). 2022;14(9):2195. doi:10.3390/cancers14092195
5. Sbrana MF, Borges RFR, Pinna FR, Brandão Neto D, Voegels RL. Sinonasal inverted papilloma: rate of recurrence and malignant transformation in 44 operated patients. Braz J Otorhinolaryngol. 2021;87(1):80–84. doi:10.1016/j.bjorl.2019.07.003
6. Long C, Jabarin B, Harvey A, Ham J, Javer A, Janjua A, et al. Clinical evidence based review and systematic scientific review in the identification of malignant transformation of inverted papilloma. J Otolaryngol Head Neck Surg. 2020;49:1. doi:10.1186/s40463-020-00420-x
7. Weindorf SC, Brown NA, McHugh JB, Udager AM. Sinonasal papillomas and carcinomas: a contemporary update with review of an emerging molecular classification. Arch Pathol Lab Med. 2019;143(11):1304–1316. doi:10.5858/arpa.2019-0372-RA
8. Mackle T, Chambon G, Garrel R, Meieff M, Crampette L. Endoscopic treatment of sinonasal papilloma: a 12-year review. Acta Otolaryngol. 2008;128(6):670–674. doi:10.1080/00016480701785009
9. Bouatay R, Farhati A, Abdelali M, Korbi AE, Ferjaoui M, Harrathi K, et al. Diagnostic strategy and therapeutic management of sinonasal inverted papilloma: our experience with review of literature. Egypt J Otolaryngol. 2022;38(1):1–8. doi:10.1186/s43163-022-00371-2
10. Franchi A, editor. Pathology of sinonasal tumors and tumor-like lesions. Cham: Springer; 2019. doi:10.1007/978-3-030-29848-7
11. Rachmadi L, Billianti Susanto YD, Manatar AF, Sitinjak D. Factors associated with dysplastic changes in sinonasal inverted papilloma: study of tumor infiltrating lymphocytes FOXP3, CD4, CD8, and p53 expression. Asian Pac J Cancer Prev. 2022;23(9):3223–3227. doi:10.31557/APJCP.2022.23.9.3223
12. Bhalla AS, Jana M. Clinico radiological series: sinonasal imaging. New Delhi: Jaypee Brothers Medical Publishers; 2018.
13. Bayne K, Olekszyk J. A rare case and location of HPV 16 positive bilateral exophytic papilloma. Otolaryngol Case Rep. 2019;13:100134. doi:10.1016/j.xocr.2019.100134
14. Lester SC, Harrison BT. Diagnostic pathology: intraoperative consultation. 3rd ed. Philadelphia: Elsevier; 2022.
15. Mo Y, Long D, Li L, Zheng Y. Exophytic nasal papilloma with acute dacryocystitis as the first symptom: a case report. BMC Ophthalmol. 2021;21:458. doi:10.1186/s12886-021-02223-8
16. Magyarosi I, Cifra J, Takács I, Somogyvári K, Móricz P. Malignant transformation of exophytic sinonasal papilloma: case report. Biomed J Sci Tech Res. 2018;12(1):8948–8951. doi:10.26717/BJSTR.2018.12.002192
17. Wang H, Liu Q, Xu R, Zhang H, Zhai C, Sun X, et al. Outcomes of sinonasal oncocytic papilloma by endoscopic approach in 69 patients. Auris Nasus Larynx. 2022;49(1):77–83. doi:10.1016/j.anl.2021.05.008
18. Zhang L, Hu C, Zheng X, Wu D, Sun H, Yu W, et al. Oncocytic Schneiderian papilloma-associated adenocarcinoma and KRAS mutation: a case report. Medicine (Baltimore). 2018;97(23):e11025. doi:10.1097/MD.0000000000011025
19. Lilja M, Viitasalo S, Hytönen M, Haapaniemi A, Hagström J, Mäkitie A. Sinonasal oncocytic papilloma—a series of 20 cases with emphasis on recurrences. Laryngoscope Investig Otolaryngol. 2019;4(6):567–572. doi:10.1002/lio2.308
20. Fu ZM, Zhao LP, Guo YY, Guan GF. Primary oncocytic Schneiderian papilloma of middle ear and eustachian tube with combined trans-oto and nasal approach: a case report. J Craniofac Surg. 2020;31(2):504–506. doi:10.1097/SCS.0000000000006136
21. Koda T, Shigihara S. Recurrent oncocytic papilloma of the middle ear. Indian J Otol. 2022;28(3):252–254. doi:10.4103/indianjotol.indianjotol_81_22

This open-access document is licensed for distribution under the terms and conditions of the Creative Commons Attribution License (http://creativecommons.org/licenses/by-nc/4.0). This permits unrestricted, non-commercial use, reproduction, and distribution in any medium, provided the original source is adequately cited and credited.