

Bilateral visual loss from sphenoidal sinus aspergillosis Onabolu OO*¹, Adeolu AA², Bodunde OT¹, Olatunji AA³

¹Department of Ophthalmology, Olabisi Onabanjo University Teaching Hospital Sagamu, ²Department of Neurological Surgery, University College Hospital Ibadan,

³Department of Radiology, Olabisi Onabanjo University Teaching Hospital, Sagamu.

Summary

Sphenoidal sinus aspergillosis is a rare disease which is difficult to diagnose due to its protean presentations. This report aims to describe bilateral loss of vision in a woman with insulin-dependent diabetes mellitus following aspergillosis of the right sphenoidal sinus. A 59-year old woman with insulin-dependent diabetes mellitus presented with a right-sided frontal headache of sudden onset which was associated with blurring of vision, all of two days duration. Her vision with correction was initially normal at 6/9 in each eye and funduscopy was normal. Two weeks into the illness, the vision became nil perception of light in the right eye. The persistence of a headache coupled with loss of vision in the left eye five months later led to neurosurgical evaluation and subsequent craniotomy. At craniotomy, pus and inflammatory tissue were found matting together the optic nerves and chiasma. Histology of the specimen showed features of aspergillosis. This case was instructive due to the rarity of sphenoidal aspergillosis/fungus ball involving the sellar/parasellar region. Delay in management can lead to blindness from optic nerve/chiasma involvement. Therefore, a high index of clinical suspicion is required although CT scan and MRI are the ultimate diagnostic tools.

Keywords: *Aspergillosis, Fungus ball, Ocular complications, Sphenoidal sinus, Visual loss, Nigeria.*

Introduction

Infection of the sphenoidal sinus occurs in 2.7% of paranasal sinus infections, and only 20% of cases are caused by fungal agents.^[1] Paranasal sinus aspergillosis is classified into invasive and non-invasive types. Fungus ball (FB) of the paranasal sinuses is a non-invasive form of aspergillosis which occurs among both immunocompetent and immunocompromised hosts.^[2,3] It is characterised by non-invasive

accumulation of dense fungal concretions or inspissated pus in the sinus cavities, often, the maxillary sinus.^[2] Fungus balls of the paranasal sinuses are uncommon, and those of the sphenoidal sinus are rare (4.5% - 26.8% of all fungus balls).^[1,3] They can be unilateral and rarely bilateral.^[2] Fungus ball is difficult to diagnose, especially when it occurs in the sphenoidal sinus because cephalgia is the main symptom; this is usually unilateral and occurs in the area supplied by the ophthalmic branch of trigeminal nerve.^[4,5] From the sphenoidal sinus, the fungal infection may spread into the intracranial cavity and cause ocular complications, and this intracranial form may be misdiagnosed as pituitary tumours.^[6]

Histological reports suggest that the most common species of *Aspergillus* which affect the sphenoidal sinus include *Aspergillus fumigatus* and *Aspergillus flavus*.^[1] Diabetes and hypertension may be associated with aspergillosis.^[1,2,4] These infections occur more frequently among post-menopausal

*Correspondence:

Dr O.O. Onabolu,
Department of Surgery,
Obafemi Awolowo College of Health Sciences,
Olabisi Onabanjo University, P.M.B 2022,
Sagamu, Nigeria.
Tel: +23480164229064
Email:tonionabolu@yahoo.com

females, but the relationship remains poorly explained.^[1,2] Some cases of paranasal sinus aspergillosis are asymptomatic, but the symptoms may include posterior rhinorrhoea, alteration of vision, disturbance of ocular motility, cacosmia and epistaxis.^[3-5]

This report describes a diabetic woman who became bilaterally blind from fungus ball of the right sphenoidal sinus. This clinical condition is reportedly rare and can be easily missed if not suspected. To the best of the authors' knowledge, this is the first report of visual loss from sinus aspergillosis in Nigeria.

Case Description

A 59-year old woman with insulin-dependent diabetes mellitus was referred to the Eye Clinic, Olabisi Onabanjo University Teaching Hospital, Sagamu, in September 2013 with the complaint of right sided headache and blurring of vision in the right (RT) eye of one-week duration. There was associated right retro-orbital pain. There was no associated cough, catarrh, fever or superficial temporal artery tenderness. Ocular examination was normal at the onset of the illness with full extraocular muscle movement.

The visual acuity was 6/9 in each eye with myopic correction, and the pupils were equal and reactive. Fundoscopy was normal with intraocular pressure (IOP) of 12mmHg in each eye. The initial diagnosis was sinusitis, and she was managed with oral cefuroxime 500mg 12 hourly for five days. Two weeks later, she developed sudden visual loss in the RT eye with only an RT afferent pupillary defect despite no change in optic nerve appearance. This development prompted referral to the Ear, Nose and Throat (ENT) Surgeon and the Neurologist. She was commenced on oral prednisolone for a suspected temporal arteritis due to a rise in ESR (34mm by Westergren method) and with adequate control of blood glucose. One week after the visual loss, the RT eye became inflamed, proptosed, fixed, with paralysis of CIII, CIV and CVI nerves. Tolosa- Hunt syndrome was suspected, and another course of antibiotic was administered along with oral ibuprofen, a non-steroidal anti-inflammatory agent. However,

prednisolone was discontinued because of loss of blood glucose control. The inflammation gradually subsided with dilatation of the pupil while the optic disc became pale. The right eye regained ocular movement but the pupil became dilated with RT optic atrophy.

The investigations included ESR, plain X-Ray of sinuses and skull to show the pituitary fossa, computerised tomography (CT) and magnetic resonance imaging (MRI) of the brain. A visual field test revealed a total loss on the right and a temporal loss on the left. The early plain x-ray reports were not helpful probably due to the small size of the lesion. Five months into the illness, the patient experienced sudden diminution of vision in the left eye. The vision was limited to counting fingers at two meters, pupillary reaction was sluggish, but the optic disc was normal. A repeat MRI showed a pre-contrast narrowing of the optic canal and hypointensity of the sella and adjacent

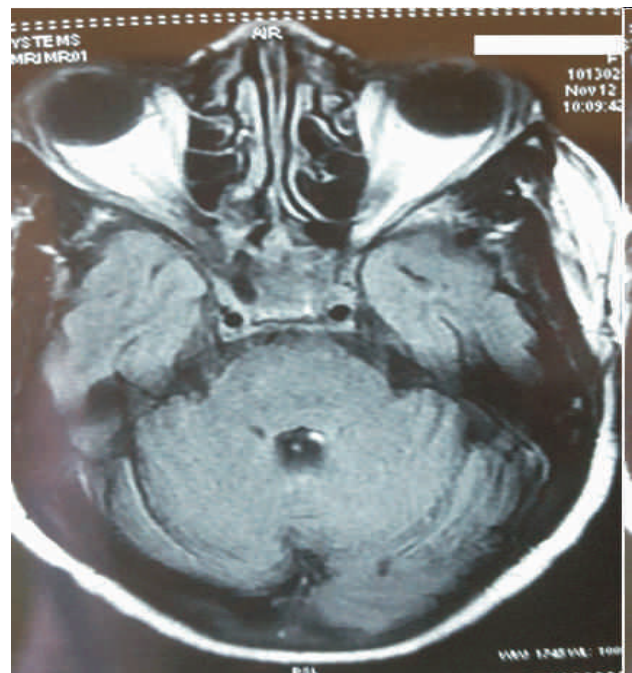


Figure 1: Non-contrast T1W MRI Axial slice at the level of the orbits and the sella showing hypointensity within the sella with consequent narrowing of RT Optic Canal.

ethmoidal sinus on T1 axial slices. (Figure 1) T1 axial slice also showed post contrast films revealed enlarged right cavernous sinus with significant enhancement extending along RT orbital apex as well as along greater wing of the right sphenoid. (Figure 2) Figure 3 also showed irregularity of the sphenoidal sinus. An infective/inflammatory lesion (Tolosa –Hunt syndrome) was suggested by the radiologist while other remote possibilities included neoplastic processes. At that point, the woman was referred to a neurosurgeon on account of

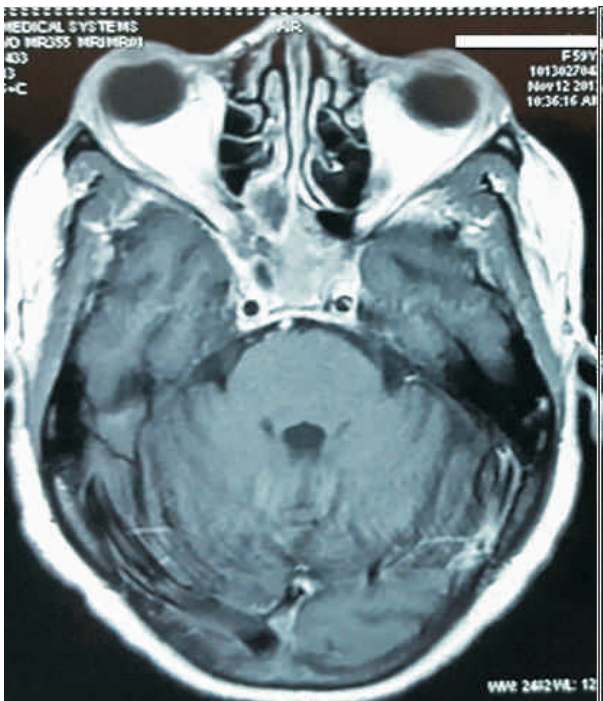


Figure 2: T1W + contrast MRI, axial slice at the level of both orbits and the sella showing an area of heterogeneous enhancement in the sella with consequent narrowing of the optic canal. Hypointensity is also noted within the right ethmoid sinus.

the visual field loss and MRI findings. The patient subsequently had craniotomy and bilateral decompression of the optic canals. At craniotomy, pus and inflammatory tissue were found matting together the optic nerves and the optic chiasma. Histology revealed *Aspergillus* species. Thereafter, she received parenteral voriconazole, which was later changed to the oral form, at the dose of 500mg twice daily. However, the patient remained blind in both eyes despite the neurosurgical and pharmacological interventions. The final

diagnosis was Fungus ball of the sphenoidal sinus extending to the chiasma.

Verbal informed consent was obtained from the patient and her two children for this case report.

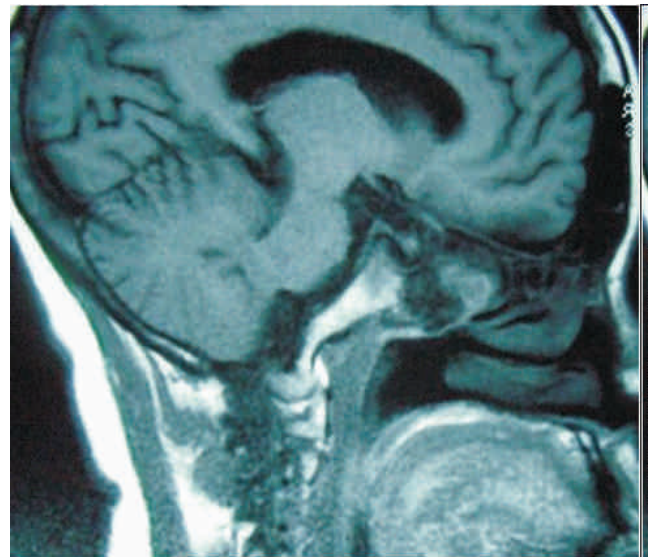


Figure 3: Para-sagittal non-contrast T1W MRI of the brain at the level of the sphenoid sinus showing irregularity of the wall with associated hypo-pneumatization of the sphenoid sinus.

Discussion

The extensive consultation that the index patient received from the ophthalmologist, the ENT surgeon, to the neurosurgeon before the diagnosis was eventually made at surgery as previously reported^[2-4] typified the difficulty in diagnosing sphenoidal aspergillosis in a resource-constrained setting. However, advancements in neuroimaging have resulted in recent prompt diagnosis of fungus ball.^[1]

In agreement with previous reports, the patient in this report was an elderly, post- menopausal female.^[1,2,4] Unlike some reported cases, there were no associated nasal symptoms in the index case.^[6,7] The persistence of cephalgia despite treatment for sinusitis supported by a visual field loss, suggesting a chiasmal lesion, prompted radiological investigations to rule out a pituitary tumour. Clinically, this case also had extension to the cavernous sinus affecting the third, fourth and sixth cranial nerves. However, the initial CT scan and MRI were negative for pituitary tumour. The repeat MRI showed an

inflammatory lesion extending into and narrowing the right orbital apex, and this explained the involvement of the optic nerve.

In the two cases reported by Tae Jen Lee *et al.*, the CT scan revealed a central dense necrotic area of the fungus which is known to contain calcium phosphate and calcium sulphate.^[9] In other CT scan and MRI-based reports, heterogeneous opacities in the sinuses associated with bone erosions were described. Sclerosis (in maxillary fungus ball) and calcifications within the sinuses (in sphenoidal fungus ball) are also known features of this condition.^[1,4,10] Karkas *et al.* had postulated visual involvement when there is a breach in the sphenoidal sinus.^[4] In the index case, there was no breach of the sinus and calcifications were not seen.

A clinical diagnosis of Tolosa–Hunt syndrome was made in this patient when the eye became inflamed, proptosed with cranial nerve palsies and patient improved with non-steroidal anti-inflammatory drugs. Although the sudden visual loss was not in support of Tolosa-Hunt syndrome, the radiological MRI findings were suggestive of the syndrome.

The anatomical intimacy between the sphenoid sinus and ocular structures in the brain can predispose to blurring of vision and ocular nerve palsies as seen in the index case. The paresis of the cranial nerves may be explained by the involvement of the cavernous sinus, which is superolateral to the sphenoid sinus or an involvement of the optic nerve just proximal to the chiasma. In the literature review by Petrick *et al.*, it was observed that the symptoms and morphologic appearance of fungus ball might be mistaken for pituitary tumour.^[6] Indeed, the index patient had investigations to exclude pituitary tumour, but the findings were not suggestive of that diagnosis until the rapid deterioration of vision in her only seeing eye prompted a surgical intervention. Rhino-orbital mucormycosis – a fungal infection of the sinuses among people with diabetes was a close differential diagnosis in the index patient, but that usually occurs in very ill patients in diabetic ketoacidosis. Sphenoidal fungus balls are notoriously difficult to diagnose prior to surgery

similar to the experience with the index patient. Therefore, a high level of suspicion is required for timely interventions aimed at saving the patient's sight and life.^[1,4] The treatment of sphenoidal fungus ball is early trans-nasal or trans-ethmoidal endoscopic sphenoidotomy.^[4-10] Recurrences are notably rare after surgery.

Conclusion

Sphenoidal fungus ball is rare, and delays in treatment can lead to destruction of the optic chiasma resulting in visual loss. Although CT scan and MRI can aid the diagnosis, a high index of clinical suspicion is required. Post-menopausal women with a persistent headache should be investigated for fungus ball.

Conflict of interest: None.

Funding: Olabisi Onabanjo University, Sagamu provided the equipment and support services.

Authors' Contributions: OOO conceived and designed the report. OOO, BOT and OAA did literature review while AAA participated in the clinical management of the patient. All the authors participated in critical revision of the manuscript and approval of the final version of the manuscript.

Publication History: Submitted 30 - January, 2017; Accepted 06 - March, 2017

References

1. Thery A, Espetallier F, Cassagnau E, Durand N, Mallard O. Clinical features of sphenoid sinus aspergillosis: A retrospective series of 15 cases. *Eur Ann Otorhinolaryngol Head Neck Dis* 2012; 129(4): 179-184.
2. Lee DH, Joo YE, Lim SC. Fungus ball of the bilateral paranasal sinuses. *Indian J Otolaryngol Head Neck Surg* 2013; 65: 320-323.
3. Kim JS, Kim BK, Hong SD, Kim HJ, Kim HY. Clinical characteristics of sphenoidal sinus fungal ball patients with visual disturbance. *Clin Exp Otorhinolaryngol*

2016; 9(4): 326-331.

4. Leroux E, Valade D, Guichard JP, Herman P. Sphenoidal fungus balls: clinical presentation and long-term follow-up in 24 patients. *Cephalgia* 2009; 29(11): 1218-1223.
5. Robey AB, O'Brien EK, Richardson BE, Baker JJ, Poage DP, Leopold DA. The changing face of paranasal sinus fungus balls. *Ann Otol Rhinolaryngol* 2009; 119(11): 2275-2279.
6. Petric M, Honegger J, Daschner F, Feuerhake F, Zentner J. Fungal granuloma of the sphenoid sinus and clivus. *Neurosurg* 2003; 52(4): 955-958.
7. Grosjean P, Weber R. Fungus ball of the paranasal sinuses: a review. *Arch Otorhinolaryngol* 2007; 264(5): 461-470.
8. Pagella F, Matti E, De Bernardi F, Semino L, Cavanna C, Marone P *et al*. Paranasal sinus ball: diagnoses and management. *Mycoses* 2007; 50: 451-456.
9. Lee TJ, Huang SF, Chen HL. Isolated sphenoidal sinus aspergillosis. *Chan Guang Med J* 2002; 25: 464-468.
10. Dufour X, Kaufmam-Lacroix C, Ferrie JC, Goujon JM, Rodier MH, Klossek JM. Paranasal sinus fungus ball epidemiology, clinical features and diagnosis. A retrospective analysis of 173 cases from a single medical centre in France, 1989-2002. *Med Mycol* 2006; 44(1): 61-67.